

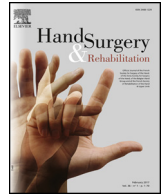

Available online at

ScienceDirect
www.sciencedirect.com

Elsevier Masson France

EM|consulte
www.em-consulte.com



Original article

A new technique in surgical treatment of congenital and spontaneous extensor tendon snapping: Dorsalization-ulnarization of the metacarpal head

Une nouvelle technique dans le traitement chirurgical du ressaut congénital et spontané des tendons extenseurs: Dorsalisation-ulnarisation de la tête métacarpienne

I.B. Ozcelik^a, A. Sari^{b,*}

^a Department of Hand and Microsurgery, Gaziosmanpaşa Hospital, Nisantasi University Vocational High School, Yeni Yüzyıl University, Cukurcesme Street, No. 51, 34245, Gaziosmanpaşa, Istanbul, Turkey

^b Department of Orthopaedics and Traumatology, Faculty of Medicine, Namık Kemal University, Kampus Street, No.1, 59030, Suleymanpasa, Tekirdag, Turkey

ARTICLE INFO

Article history:

Received 22 November 2020

Received in revised form 21 June 2021

Accepted 8 July 2021

Available online 4 August 2021

Keywords:

Extensor tendon dislocation

Metacarpal transposition

Pseudo-triggering

Sagittal band injury

Wide-awake anesthesia

Mots-clés:

Anesthésie éveillée

Lésion de la bandelette sagittale

Luxation du tendon extenseur

Pseudo-ressaut

Transposition métacarpienne

ABSTRACT

The present study reports results of a metacarpal transposition technique we have developed for congenital and spontaneous extensor tendon snapping. Six patients with a mean age of 14 years (range: 12–19 years) were included and evaluated retrospectively. They had Rayan–Murray type-3 atraumatic chronic extensor tendon instability: 2 on the middle finger, 3 on the ring finger, and 1 on the index and middle fingers. In selecting the cases, preoperative examination included elevation of the metacarpals to check whether this decreased the tendon snapping, and patients in whom no snapping persisted were scheduled for surgery. Pre- and post-operative pain at rest and in activity was assessed on visual analog scale (VAS), and the QuickDASH test was administered. Pre- and post-operative active and passive ranges of metacarpophalangeal motion were measured, as was grip strength on a Jamar dynamometer. Mean follow-up was 38 months (range: 26–42 months). Postoperatively, pain during activity and QuickDASH score showed significant improvement. No wound problems or recurrence were encountered. There were no significant postoperative changes in active and passive joint range of motion. At follow-up examination, no physical therapy needed to be prescribed and no limitation of motion was observed. For tendon snapping, in which treatment is technically difficult and may lead to problems, we believe that our easily applicable minimally traumatizing technique does not restrict joint motion and is an appropriate solution for patients with positive elevation test.

© 2021 SFCM. Published by Elsevier Masson SAS. All rights reserved.

R É S U M É

Dans cette étude, nous avons voulu présenter les résultats de la technique de transposition métacarpienne que nous avons définie pour les cas de ressaut congénital et spontané des tendons extenseurs. Six cas d'un âge moyen de 14 ans (intervalle : 12 à 19 ans) ont été inclus dans l'étude et évalués rétrospectivement. Les patients présentaient une instabilité chronique atraumatique du tendon extenseur de type 3 de Rayan et Murray: deux sur le majeur, trois sur l'annulaire et un sur l'index et le majeur. Lors de la sélection des cas, l'examen clinique préopératoire cherchait si l'élévation métacarpienne diminuait le ressaut. Une intervention chirurgicale a été prévue pour les patients chez qui l'élévation faisait disparaître le ressaut. Les scores préopératoire et postopératoire d'échelle visuelle analogique (EVA) pour la douleur ont été mesurés pendant le repos et l'activité, et des tests QuickDASH ont été effectués. L'amplitude de mouvement active et passive de l'articulation métacarpo-phalangienne

* Corresponding author.

E-mail addresses: bulent-ozcelik@hotmail.com (I.B. Ozcelik), drortopedist@yahoo.com (A. Sari).

a été mesurée en préopératoire et en postopératoire. La force de préhension a été mesurée avant et après l'opération à l'aide d'un dynamomètre Jamar. Le suivi moyen était de 38 mois (intervalle : 26 à 42 mois). En postopératoire, le score à l'EVA pendant l'activité et les scores QuickDASH ont montré une amélioration significative. Aucun problème de plaie ou de récurrence n'a été observé chez aucun patient. Aucun changement significatif n'a été observé dans les valeurs de l'amplitude de mouvement actifs et passifs des articulations en postopératoire. Lors de l'examen de suivi, aucune physiothérapie n'avait été nécessaire et aucune limitation des mouvements n'a été observée. Dans les cas de ressaut du tendon, qui est techniquement difficile à résoudre et peut générer des problèmes, nous pensons que cette technique facile à appliquer et peu traumatisante, ne limite pas la mobilité, c'est une solution de traitement appropriée pour les patients chez qui un résultat positif est obtenu lors du test d'élévation.

© 2021 SFCM. Publié par Elsevier Masson SAS. Tous droits réservés.

Introduction

The sagittal band (SB) is the retinacular structure at the metacarpophalangeal (MCP) joint, and is the primary stabilizer of the extensor digitorum communis (EDC) [1]. The juncturae tendinum (JT) are composed of connective tissue located more proximally between the EDC tendons and act as a secondary stabilizer [2]. The SB starts in the volar region from the volar plate, flexor tendon sheath and deep transverse metacarpal ligament, and branches to the joint capsule and collateral ligaments [3]. Besides inflammatory diseases such as rheumatoid arthritis, SB-induced instability may arise from traumatic rupture, spontaneous rupture due to repeated low-energy activity, or congenital SB weakness or absence [4]. Instability is most common in the middle finger, due to the round structure of the tendon and its weaker fibrous attachments [5]. The Rayan-Murray classification is generally used to categorize SB lesions (Table 1) [6].

Although several treatment methods for extensor tendon snapping (ETS) have been described, there is still no consensus [7]. The present study reports our clinical experience with patients treated by dorsalization and ulnarization of the metacarpals using microfiber sutures passed through the bone.

Patients and methods

Between January 2012 and January 2018, 6 female patients (mean age: 14 years; range: 12–19 years) with Rayan-Murray type-3 chronic atraumatic extensor tendon instability were included. The instability involved the dominant right hand in 5 cases and the non-dominant left hand in 1. ETS was thought to be congenital in 3 cases, with history of trigger finger surgery at an early age due to snapping complaints. The complaints of these 3 patients worsened after release. The other 3 patients had no prominent trauma history; onset of ETS was spontaneous, with progression throughout the previous year (Table 2). The patients had no significant symptoms of laxity. Active and passive MCP joint motion was normal in all patients, but they experienced painful snapping in 40–70° active flexion (video S1). In indicating surgery, it was checked whether snapping disappeared after metacarpal dorsalization, and surgery was recommended for patients whose complaint regressed. In the spontaneous cases, preoperative

metacarpal fixation by taping and subsequent physical therapy were applied for at least 3 months.

Approval was obtained from our institutional review board.

Surgical technique

All surgical procedures were performed under wide-awake anesthesia. The affected metacarpal was dorsalized by pushing it from the volar side. Microfiber sutures were passed on both sides with the help of K-wires for snapping in the middle and ring fingers. The ends of the suture, which was passed in a U-shape through all three metacarpals, were tied and the middle metacarpal was fixed in the dorsal position (Fig. 1). The appropriateness of metacarpal dorsalization was assessed by observing whether tendon snapping persisted during active and passive movements and whether centralization was maintained. Dorsalization of the middle metacarpal and ulnarization of the index finger were performed differently from the other cases in the patient with snapping in the index and middle fingers (Patient no. 3), using microfiber sutures (Table 2). In all operated patients, tendon subluxation toward the ulnar side was centralized after dorsalization of the metacarpal, and snapping was reduced (Video S2). No postoperative splinting or taping was applied.

Pre- and post-operative pain on visual analog scale (VAS) was measured at rest and in activity, and the Disabilities of the Arm, Shoulder and Hand (QuickDASH) test was administered. On the second postoperative day, pain at rest, persistent tendon dislocation and cosmetic appearance were assessed. At the 12-month follow-up, ability to perform daily tasks was investigated. Active and passive MCP range of motion (ROM) was measured pre- and post-operatively on a standard goniometer and was compared with contralateral values. Grip strength was measured pre- and post-operatively on a Jamar dynamometer (Sammons Preston™, Bolingbrook, IL, USA). ROM and grip exercises were begun in the early postoperative period insofar as the patient could tolerate pain. In the third month, patients could return to sport and manual work.

Statistical methods

Data were reported as mean and standard deviation. Normal distribution was checked on Shapiro-Wilk test and histograms. Pre- to post-operative measurements were compared on t-test for dependent groups. VAS scores were analyzed on Friedman test. P values <0.05 were considered statistically significant.

Results

Mean follow-up was 38 months (range: 26–42 months). Preoperative, postoperative day 2, 12th month and final follow-up VAS scores were 1 ± 1.4 , 1.5 ± 0.6 , 0 and 0, respectively, at rest ($p = 0.076$), and 6.5 ± 1.3 , 2.75 ± 0.5 , 0.25 ± 0.5 and 0.25 ± 0.5

Table 1
The Rayan Murray classification.

Type 1	Simple contusion. There is no tendon instability.
Type 2	The tendon is subluxated, but the metacarpal head is still in contact with the tendon.
Type 3	The tendon is dislocated. The tendon has risen between the two metacarpal heads and its contact with the bone is lost.

Table 2
Descriptive data of the patients.

Case n°	Involved finger	Time between symptom onset and surgery	Classification of snapping	Surgery
1	3 rd	8 years	Congenital	Dorsalization
2	3 rd	9 years	Congenital	Dorsalization
3	2 nd and 3 rd	8 years	Congenital	Dorsalization and ulnarization
4	4 th	6 months	Spontaneous	Dorsalization
5	4 th	8 months	Spontaneous	Dorsalization
6	4 th	8 months	Spontaneous	Dorsalization

during activity ($p = 0.018$). Mean QuickDASH score was 34.1 ± 18.4 preoperatively and 3.98 ± 2.15 postoperatively ($p < 0.001$), and mean grip strength was respectively 22.75 ± 2.63 kg and 30.25 ± 4.27 kg ($p = 0.071$) (Table 3).

MCP ROM at day 2 showed no impairment compared to the contralateral hand. Postoperatively, mean active flexion and extension were $87.8^\circ \pm 1.1^\circ$ and $20^\circ \pm 3.7^\circ$, respectively, and mean passive flexion and extension were $88.6^\circ \pm 1.7^\circ$ and $25.3^\circ \pm 2.8^\circ$. No limitation of motion was detected in non-operated fingers. Cosmetic appearance was excellent, since surgery was performed with only two 0.5-cm incisions. There were no wound problems or recurrence. At follow-up, no physical therapy needed to be prescribed and no limitation of motion was observed.

Discussion

Although rare, EDC tendon instability is the source of several serious complaints such as pain, weakness and snapping [8]. Several treatment methods have been described, but consensus is yet to be achieved.

Conservatively, orthoses and taping techniques that keep the MCP joint in extension and limit flexion ($0\text{--}60^\circ$) are used [9]. Several authors reported variable results for spontaneous snapping and highlighted the importance of initiating treatment during the early period. Peelman et al. applied conservative treatment in a large series of 24 spontaneous cases and observed significantly more persistent tendon snapping in the spontaneous group than in the traumatic one ($p < 0.009$) [10]. In spontaneous cases, treatment success was 100% when begun in the first 3 weeks, 67% when begun between 3 and 6 weeks, and 57% when begun after 6 weeks. Although the conservative approach has a role in the treatment of spontaneous cases, finger movements are restricted for approximately 6–10 weeks. Also, orthoses require patient compliance [1]. We applied taping for 2 months in 3 patients with spontaneous snapping (Video S3); however, due to the repeated taping, the patients encountered difficulties and adaptation problems when performing daily activities. Nevertheless, this did not deter us from attempting conservative treatment before surgery.

Various surgical interventions for tendon snapping have been described [11]. Series of spontaneous cases in which the SB was repaired in first line have been reported. In 26 cases with spontaneous SB rupture, Hong et al. performed primary repair

using the interlocking suture technique and observed pain only in 1 case at the 6th month follow-up [12]. Ishizuki reported that SB repair on the damaged radial side alone was not sufficient in spontaneous cases and required additional anchor sutures [13]. It has been reported that primary repair is not sufficient alone and that release of the SB on the ulnar side or capsular repair should be associated [14]. In chronic cases, primary repair is difficult due to the atrophy of SB remnants [7,15].

Numerous reconstructive interventions are used in congenital or spontaneous cases. Ulnar-based capsular flaps, distal-based partial slips of extensor indicis proprius and EDC, lumbrical tendon transfers, JT, palmaris longus or fascia lata reconstructions are used for centralization of the tendon [12,16]. In their case series of spontaneous snapping, Shiode and Moritomo [17] reported that they required 3 weeks' buddy taping after reconstruction. Recovery was uneventful in all cases; however, complications such as infection or MCP joint contracture may occur. Ozcanli et al. reported successful results following reconstruction with ulnar-based rectangular capsular flap in a patient with congenital dislocation of the middle and ring finger tendons [18]. Reconstructive interventions may be more complicated: sometimes additional incisions may be needed for increased stability and early mobilization, 3–4 weeks' immobilization may be required, and complications such as joint stiffness or infection may develop [7].

As seen in the present 3 congenital cases, patients with ETS can be operated on in the same way as those with trigger finger. This condition, called pseudo-triggering, is observed especially in congenital extensor tendon dislocation [19]. This possibility should be considered in order to avoid unnecessary surgical intervention (Video S4).

Accurate identification of the primary pathology is important in treatment planning. Finger extension has highly complex biomechanics. Both the SB and the JT play an important role in maintaining a stable extension movement [20]. The SB and JT are dynamic structures, and move together with the EDC during MCP joint movement [21]. In addition, the SB prevents tendon slippage, bowstring and excess excursion, while the JT adjusts the force distribution between the extensor tendons, preventing overloading on the SBs [2]. After the tendon luxates to the ulnar side, tension in the JT increases, causing ulnar snapping over time in the neighboring tendon to which the JT is attached [20]. In one of the present congenital cases, snapping started in the middle finger,

Table 3
Clinical evaluation of pain, QuickDASH functional score and grip strength before and after surgical treatment.

	Preoperative	Postoperative day 2	12-month follow-up	Final follow-up	P
Pain on VAS at rest	1.0 ± 1.4	1.5 ± 0.6	0.0 ± 0.0	0.0 ± 0.0	0.076
Pain on VAS during activity	6.5 ± 1.3	2.7 ± 0.5	0.2 ± 0.5	0.2 ± 0.5	0.018
QuickDASH functional score	34.1 ± 18.4			3.9 ± 2.1	<0.001
Grip strength (kg)	22.7 ± 2.6			30.2 ± 4.2	0.071

VAS: visual analog scale. P values in bold indicate significant difference between the three groups.

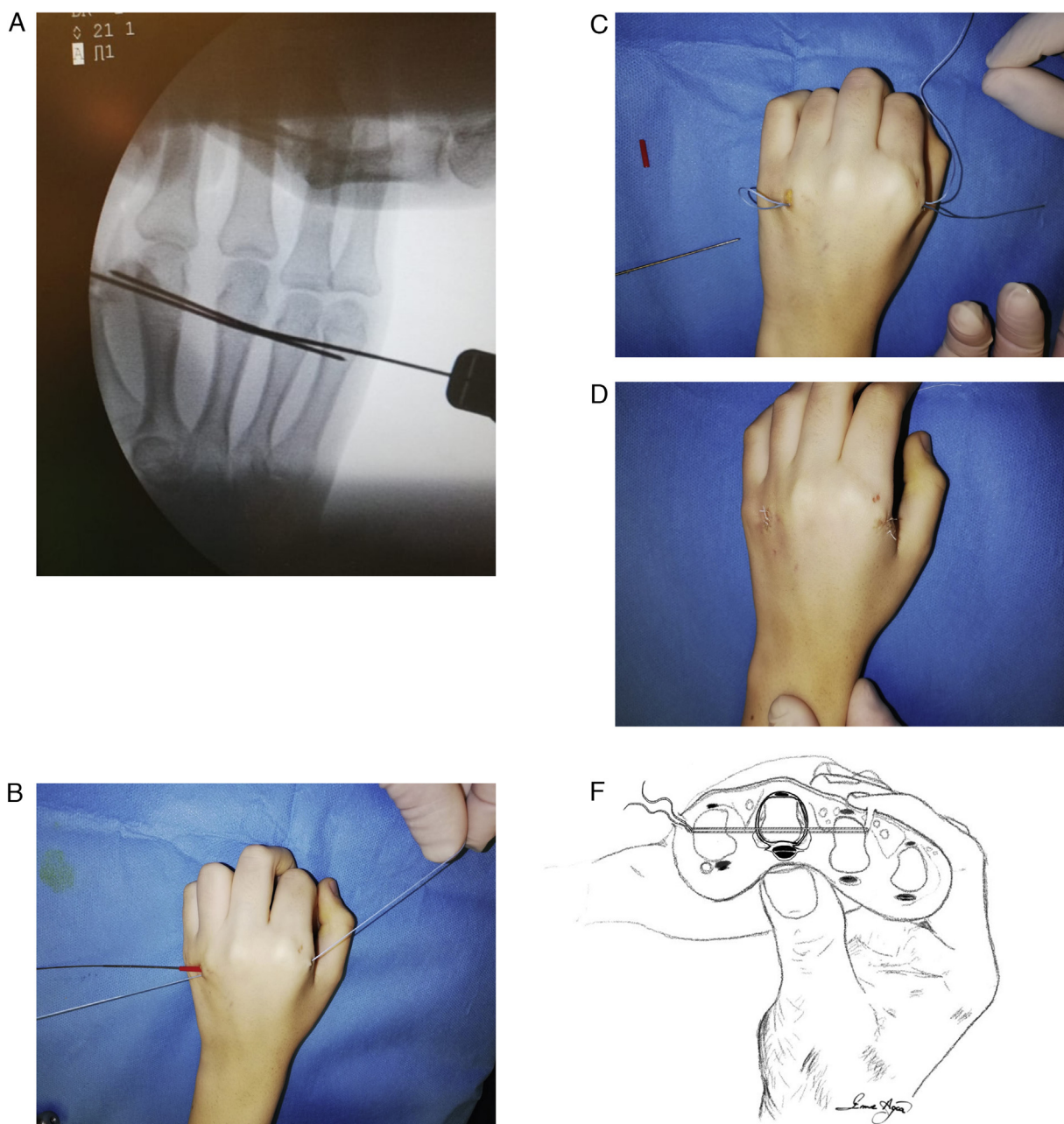


Fig. 1. Passing the K-wire through the 2nd, 3rd and 4th metacarpals following dorsalization of the metacarpal (a). Passing the microfiber suture through the metacarpals (b). Tying the U-shaped suture (c). Appearance after procedure (d). Axial illustration of our technique (e).

disrupting the biomechanics of the index finger and causing complaints, which is a finding that supports the above mechanism. The connections the lumbrical and interossei muscles make on the volar aspect of the MCP joint and then with the SBs are effective in dynamic stabilization of the EDC tendons [3]. We believe that displacement of the MCP joint to the dorsal side is beneficial for this dynamic stabilization, by increasing the tension of the sagittal bands. We believe that this effect is similar to that of conservative treatment, but can be considered to have a permanent internal splint effect.

During surgical exploration of a congenital dislocation, Ozcanli et al. reported that only the superficial layer of the SB was thin and that the JT did not exist [18]. Ishizuki reported that, in spontaneous instability, the superficial layer of the SB was ruptured, whereas in traumatic instability both the deep and superficial layers were

ruptured [13]. In 26 cases with Rayan–Murray types 2 and 3 spontaneous rupture, Hong et al. detected partial or complete tear only in the superficial layer during open surgery [12]. Ishizuki identified a groove on the deep layer of the SB, on which the extensor tendon was placed [13]. Chinchalkar et al. reported that radial side weakness in the SB caused volar subluxation in the MCP joint and that the EDC was pulled over the metacarpal head due to the structural connection between the volar plate and SBs during extension of the MCP joint [20].

These findings suggest that, in congenital and spontaneous extensor tendon dislocation, along with dorsalization of the metacarpals, increased tension in deep fibers is effective in ensuring stability. We tested this hypothesis by checking whether ETS regressed after dorsalization of the metacarpals, which it did in 6 patients. No other patients presented with ETS during the study,

and we applied no other treatment method. However, this does not mean that dorsalization decreases ETS in all patients; the condition should be evaluated on a case-by-case basis.

Surgery was performed under wide-awake anesthesia, which allowed dynamic evaluation. Metacarpal transposition could be adjusted intraoperatively and the sutures were tied at that degree of correction. The efficacy of reconstruction performed under general anesthesia can only be evaluated on passive movements, which is far from accurate in simulating the forces causing tendon instability. This may result in post-surgical snapping or flexion restriction. Unlike techniques previously reported, the metacarpal transposition technique does not require any postoperative immobilization. Significant improvements in pain during activity and in QuickDASH score were found after implementation of the technique.

The present study had some limitations. The number of cases was small, due to the low incidence of the condition, and there was no control group. However, follow-up was quite long, and it was a promising finding that there were no recurrences arising in the late period (Video S5).

The present study was mainly based on the disappearance of snapping with change in metacarpal position during examination in patients with ETS. This mechanism of action needs to be clarified on imaging and in biomechanical studies.

Conclusion

ETS regressed after metacarpal dorsalization and/or ulnarization, and patients returned to daily life quickly and smoothly, with minimal cosmetic defect, no limitation of motion and no loss of time in the postoperative period. We believe that the metacarpal transposition technique can be successfully applied in patients with congenital and spontaneous ETS.

Contributorship

Ismail Bulent OZCELIK: Research, conceptualization, protocol development, gaining ethical approval, patient recruitment, data analysis, review & editing.
Abdulkadir SARI: Research, conceptualization, writing the original draft, review & editing.

Funding

The authors received no financial support for the research, authorship, and/or publication of this article.

Conflict of interest

The authors have no conflicts of interest to declare.

Acknowledgment

We thank Emre Agca for his illustrations presented in this study.

Appendix A. Supplementary data

Supplementary material related to this article can be found, in the online version, at doi:<https://doi.org/10.1016/j.hansur.2021.07.008>.

References

- [1] Young CM, Rayan GM. The sagittal band: anatomic and biomechanical study. *J Hand Surg Am* 2000;25:1107–13.
- [2] von Schroeder HP, Botte MJ, Gellman H. Anatomy of the juncturae tendinum of the hand. *J Hand Surg Am* 1990;15:595–602.
- [3] Rayan GM, Murray D, Chung KW, Rohrer M. The extensor retinacular system at the metacarpophalangeal joint. Anatomical and histological study. *J Hand Surg Br* 1997;22:585–90.
- [4] Catalano 3rd LW, Gupta S, Ragland 3rd R, Glickel SZ, Johnson C, Barron OA. Closed treatment of nonrheumatoid extensor tendon dislocations at the metacarpophalangeal joint. *J Hand Surg Am* 2006;31:242–5.
- [5] Kettelkamp DB, Flatt AE, Moulds R. Traumatic dislocation of the long-finger extensor tendon. A clinical, anatomical, and biomechanical study. *J Bone Joint Surg Am* 1971;53:229–40.
- [6] Rayan GM, Murray D. Classification and treatment of closed sagittal band injuries. *J Hand Surg Am* 1994;19:590–4.
- [7] Kang L, Carlson MG. Extensor tendon centralization at the metacarpophalangeal joint: surgical technique. *J Hand Surg Am* 2010;35:1194–7.
- [8] Kang N, Smith P. Congenital absence of the juncturae tendini contributing to dislocation of the extensor tendons. *J Hand Surg Am* 2001;26:501–5.
- [9] Tubiana R, Thomine JM, Mackin E. Examination of the hand and wrist, 2nd ed., New York, NY: Informa Healthcare; 1998.
- [10] Peelman J, Markiewitz A, Kiefhaber T, Stern P. Splintage in the treatment of sagittal band incompetence and extensor tendon subluxation. *J Hand Surg Eur* 2015;40:287–90.
- [11] Wheeldon FT. Recurrent dislocation of extensor tendons in the hand. *J Bone Joint Surg Br* 1954;36:612–7.
- [12] Hong IT, Oh CH, Sim YS, Han SH. Direct repair of the sagittal band for extensor tendon subluxation caused by finger flicking. *Orthopäde* 2017;46:755–60.
- [13] Ishizuki M. Traumatic and spontaneous dislocation of extensor tendon of the long finger. *J Hand Surg Am* 1990;15:967–72.
- [14] Arai K, Toh S, Nakahara K, Nishikawa S, Harata S. Treatment of soft tissue injuries to the dorsum of the metacarpophalangeal joint (Boxer's knuckle). *J Hand Surg Br* 2002;27:90–5.
- [15] Andrus RJ, Herndon JH. Ulnar subluxation of the extensor digitorum communis tendon: a case report and review of the literature. *Iowa Orthop J* 1993;13:208–13.
- [16] Wu K, Masschelein G, Suh N. Treatment of sagittal band injuries and extensor tendon subluxation: a systematic review. *Hand (N Y)* 2020. 1558944719895622.
- [17] Shiode R, Moritomo H. Tether creation between the second and third extensor digitorum communis for third extensor tendon subluxation at the metacarpophalangeal joint. *Tech Hand Up Extrem Surg* 2018;22:146–9.
- [18] Ozcanli H, Ozenci AM, Ozdemir H. Congenital dislocation of the extensor tendon of the hand. *J Plast Surg Hand Surg* 2012;46:447–9.
- [19] Çırpar M, Dağlar B, Oktaş B. Congenital extensor tendon dislocation causing pseudotriggering of the little finger. *Acta Orthop Traumatol Turc* 2017;51:429–31.
- [20] Chinchalkar SJ, Barker CA, Owsley B. Relationship between juncturae tendinum and sagittal bands. *J Hand Microsurg* 2015;7:96–101.
- [21] Chinchalkar SJ, Pitts S. Dynamic assist splinting for attenuated sagittal bands in the rheumatoid hand. *Tech Hand Up Extrem Surg* 2006;10:206–11.