

Atypical presentation of tuberculous tenosynovitis of the hand

Berkan Mersa, Ismail Bülent Özçellik, Özgür Pllanci and Samet Vasfi Kuvat

J Hand Surg Eur Vol 2010 35: 429

DOI: 10.1177/1753193409353499

The online version of this article can be found at:

<http://jhs.sagepub.com/content/35/5/429>

Published by:



<http://www.sagepublications.com>

On behalf of:

British Society for Surgery of the Hand



Federation of the European Societies for Surgery of the Hand



Additional services and information for *Journal of Hand Surgery (European Volume)* can be found at:

Email Alerts: <http://jhs.sagepub.com/cgi/alerts>

Subscriptions: <http://jhs.sagepub.com/subscriptions>

Reprints: <http://www.sagepub.com/journalsReprints.nav>

Permissions: <http://www.sagepub.com/journalsPermissions.nav>

Atypical presentation of tuberculous tenosynovitis of the hand

Dear Sir,

Tuberculosis (TB) may affect almost any body tissue. Musculoskeletal TB, which may affect bones, tendons and bursa, is a rare form of extrapulmonary disease and occurs in about 1.3% of cases (Lakhanpal et al., 1987). The diagnosis of TB tenosynovitis is often delayed. Typically, patients with TB synovitis describe local pain and have a swelling on the hand with limitation in the range of motion of the fingers (Lakhanpal et al., 1987; Sueyoshi et al., 1996).

We report a case with atypical involvement of the hand. A 27-year-old butcher was referred to our clinic complaining of a painless swelling on the right hand for more than a year. Physical examination revealed hyperaemic palpable masses on the palmar surface of the thumb, the small finger and the ulnar region of the wrist. The limitations in the ranges of motion in the interphalangeal joint of the thumb and distal and proximal interphalangeal joints of the small finger were 10°, 20° and 25°, respectively.

Soft tissue masses only were seen on radiographs, with no sign of bone destruction. MRI (post-contrast study) revealed heterogenous synovial lesions extending to the wrist around the flexor sheaths of the thumb and the small finger (Fig 1). Because of these findings, an open biopsy of the tenosynovium from the wrist was done. Macroscopically there was thickening of synovium accompanied by numerous rice-like particles. Histology showed granulomatous lesions containing multinuclear giant cells with occasional central necrosis, epithelioid fibroblasts and mononuclear inflammatory cells. These findings were characteristic of tuberculosis (Fig 2). Africanum and Bovinum types of tuberculosis were isolated by BACTEC. The patient was treated with antitubercular drugs (isoniazid, rifampin, pyrazinamide and ethambutol) for 9 months. The lesions regressed dramatically 6 weeks after starting these drugs. A nearly complete recovery of range of motion was observed at a 1 year follow-up.

Further assessment of the patient and his family did not reveal any other physical or radiological evidence of the disease. Except for a positive tuberculin test, all his routine biochemical tests were normal.

There have been a few cases of flexor tenosynovitis caused by *Mycobacterium bovis* (Cooke et al., 2002). Most of them were related to occupation. In the light of our findings, we believe that the most likely source of contagion was an animal. To the best of the authors' knowledge, this is the first case in which tuberculous tenosynovitis occurred in two different locations on the same hand.

Conflict of interests

None declared.

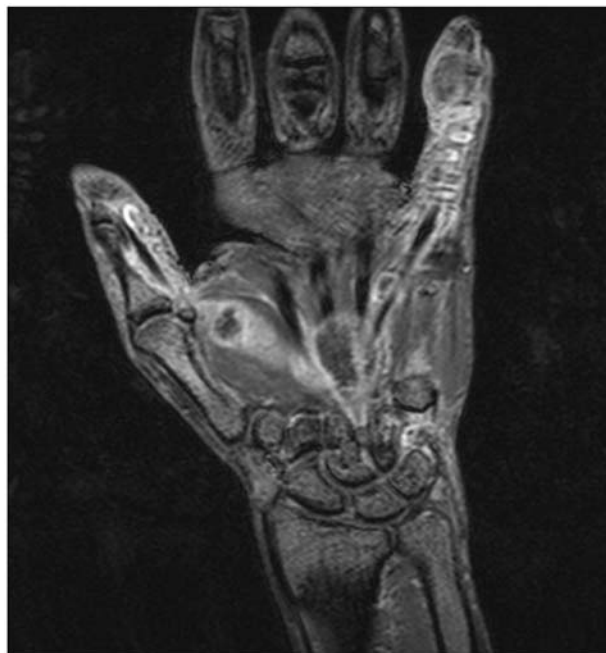

Fig 1 MR image of tuberculous tenosynovitis involving the thumb and small fingers. Note the extensions to the wrist.

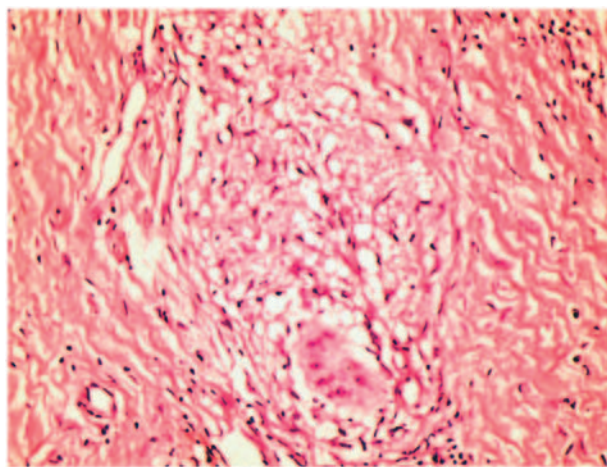


Fig 2 Histological appearance of tuberculous tenosynovitis.

References

- Cooke MM, Gear AJ, Naidoo A, Collins DM. Accidental *Mycobacterium bovis* infection in a veterinarian. *N Z Vet J.* 2002, 50: 36–8.
- Lakhanpal S, Linscheid RL, Ferguson RH, Ginsburg WW. Tuberculous fasciitis with tenosynovitis. *J Rheumatol.* 1987, 14: 621–4.
- Sueyoshi E, Uetani M, Hayashi K, Kohzaki S. Tuberculous tenosynovitis of the wrist: MRI findings in three patients. *Skeletal Radiol.* 1996, 25: 569–72.

Berkan Mersa, MD, İsmail Bülent Özçelik, MD
 Özgür Pıllancı, MD and Samet Vasfi Kuvat, MD
*İst-El Hand Surgery, Microsurgery and Rehabilitation
 Group, Gaziosmanpaşa Hospital (Mersa, Ozcelik);
 Bağcılar Training and Research Hospital, Department of
 Plastic and Reconstructive Surgery (Pıllancı); and
 İstanbul Training and Research Hospital Department of
 Plastic and Reconstructive Surgery, İstanbul, Turkey
 (Kuvat).*
 E-mail: ozgurpillanci@yahoo.com

© The Author(s), 2010.
 Reprints and permissions: <http://www.sagepub.co.uk/journalsPermissions.nav>
 doi: 10.1177/1753193409353499 available online at <http://jhs.sagepub.com>

Abnormal innervation of the triceps brachii muscle by the ulnar nerve

Dear Sir,

Anatomy textbooks describe that the radial nerve supplies the motor branches to the long, lateral and medial heads of the triceps muscle. But others nerves, such as the axillary (de Sèze et al., 2004, Rezzoud et al., 2002) or the ulnar nerve, could innervate different heads of this muscle.

During a routine dissection of the shoulders and upper limbs of a 79-year-old female cadaver, a medial head of the left triceps muscle with a motor branch from the ulnar nerve was found. The ulnar nerve was identified in

the proximal arm with the axillary artery and pierced the medial intermuscular septum. It went from the anterior to the posterior compartment of the upper arm and ran obliquely along the medial border of the medial head of the triceps muscle. It descended with the superior ulnar collateral artery. Ten centimetres above the elbow, a motor branch from the ulnar nerve went into the medial head of the triceps. This motor branch penetrated into the muscle in an oblique plane (Fig 1) and then divided within the muscle into several small branches. We could not identify any branch from the radial nerve to this head of the muscle.

Anatomical variations of nerve innervations in the upper limb are infrequent, but have a clinical, diagnostic and surgical relevance. When examining patients with traumatic injury involving the axillary (Rezzouk et al., 2002) or the ulnar nerve, strength of the long and middle head of the triceps brachii muscle must also be assessed. The posterior aspect of the distal humerus and elbow joint has been approached using a triceps splitting, triceps reflecting, posterolateral Kocher, posteromedial Bryan–Morrey, and modified Macausland transolecranon approaches. Surgeons need to be aware of possible variations in nerve supply to avoid an iatrogenic injury (Özer et al., 2006). These variations also need to be known for electrophysiologic interpretation (Gonzalez et al., 2001).

There are several examples of upper limb muscles that are supplied by other than the usual nerves, such as the brachial muscle, which can have a double innervation

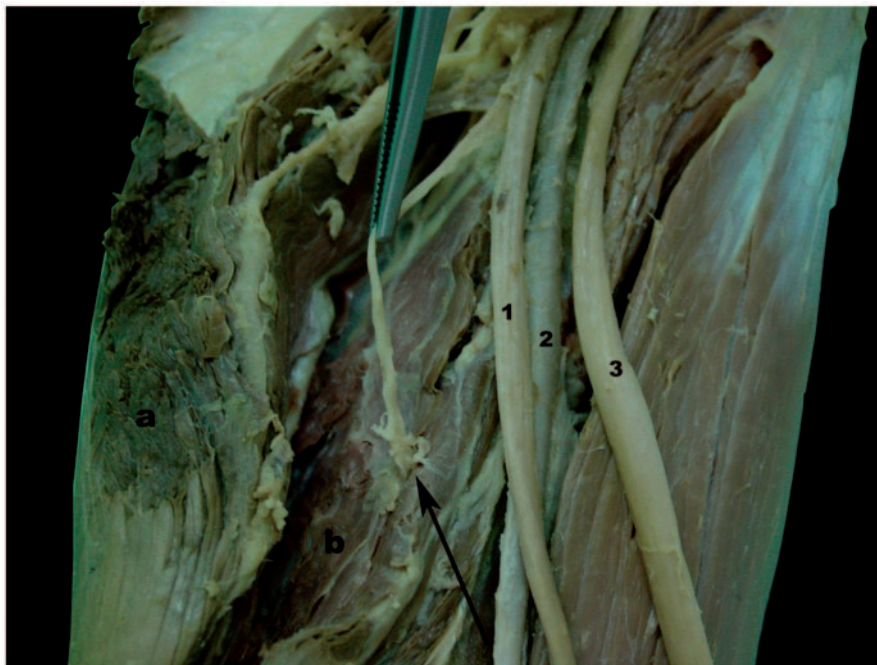

Fig 1 Left upper limb. The long head of the triceps muscle (a) is cut in order to see the medial head (b) and shows the branch (arrow) of the ulnar nerve (1) entering into the medial head of the triceps muscle. Anterior to the ulnar nerve, the brachial artery (2) and the median nerve (3) are seen.